

RESEARCH ARTICLE

Open Access



# Ameliorative effects of Xue-Fu-Zhu-Yu decoction, Tian-Ma-Gou-Teng-Yin and Wen-Dan decoction on myocardial fibrosis in a hypertensive rat mode

Guohua Zhang<sup>1</sup>, Guang Yang<sup>2</sup>, Yan Deng<sup>1</sup>, Xiangling Zhao<sup>2</sup>, Yingbao Yang<sup>2</sup>, Jinjun Rao<sup>2</sup>, Wenya Wang<sup>2</sup>, Xin Liu<sup>1</sup>, Jian He<sup>2</sup> and Lin Lv<sup>2\*</sup>

## Abstract

**Background:** Xue-Fu-Zhu-Yu decoction (XFZYD), Tian-Ma-Gou-Teng-Yin (TMGTY) and Wen-Dan decoction (WDD) are Chinese herbal formulas used to treat hypertension and cardiovascular diseases in traditional Chinese medicine (TCM). The goal of our study is to determine if XFZYD, TMGTY or WDD treatment ameliorated myocardial fibrosis in spontaneously hypertensive rats (SHRs) and to identify the mechanisms underlying any beneficial effects observed during the courses of the investigation.

**Methods:** Forty-five 12-week-old male spontaneously hypertensive rats and five age-matched male Wistar-Kyoto control rats were studied for 16 weeks. Each day 6 g·kg<sup>-1</sup> or 12 g·kg<sup>-1</sup> of XFZYD, TMGTY or WDD was orally administered at the indicated dose, and the systolic blood pressure (SBP) of all rats was measured using the tail-cuff method. Collagen levels were measured via hydroxyproline content assays and histological examination. Transforming growth factor beta-1 (TGF-β<sub>1</sub>) protein levels were determined via immunohistochemical and Western blot analysis. TGF-β<sub>1</sub> mRNA levels were assessed using real-time reverse transcription polymerase chain reaction.

**Results:** Systolic blood pressure was unaffected, but collagen and TGF-β<sub>1</sub> levels in SHRs treated with captopril and XFZYD (12 g·kg<sup>-1</sup>) were significantly reduced when compared with untreated control SHRs. Administration of 12 g·kg<sup>-1</sup> XFZYD increased myocardial cell protection and decreased TGF-β<sub>1</sub> mRNA and protein expression when compared with the other SHR treatment groups.

**Conclusions:** XFZYD treatment demonstrated a superior ability to reverse myocardial fibrosis when compared with WDD or TMGTY treatment in SHRs. XFZYD also decreased TGF-β<sub>1</sub> mRNA and protein expression, suggesting that the TGF-β<sub>1</sub> signaling pathway plays a role in the therapeutic effects of XFZYD treatment.

**Keywords:** Xue-Fu-Zhu-Yu decoction, Tian-Ma-Gou-Teng-Yin, Wen-Dan decoction, Hypertension, Myocardial fibrosis, SHR, TGF-β<sub>1</sub>

\* Correspondence: lynnlv1@163.com

Guohua Zhang and Guang Yang are co-first author.

<sup>2</sup>School of Pharmaceutical Sciences, Southern Medical University, 1838 Guangzhou Avenue North, Guangzhou, P. R. China

Full list of author information is available at the end of the article



## Background

Hypertension is one of the most common diseases afflicting humans worldwide. It is a major risk factor for stroke, myocardial infarction, vascular disease and chronic kidney disease. Hypertension may contribute to heart failure in as many as 50 to 60 % of patients. It contributes to 50 % of ischemic strokes and increases the risk of hemorrhagic stroke. Hypertension is the primary cause for myocardial fibrosis, and contributes to the pathophysiology of cardiac damage [1, 2]. Hypertension causes a sustained increase in cardiac pressure overload, triggering excessive proliferation and the accumulation of interstitial and perivascular collagen fibers that leads to myocardial fibrosis [3]. Myocardial fibrosis is an integral component of chronic heart disease [4], and it is increasingly thought to have a key role in disease progression as well [5]. Unfortunately, no specific therapies capable of halting or reversing myocardial fibrosis are currently available. Therefore, myocardial fibrosis prevention and treatment is a subject of great clinical value and public health interest.

Transforming growth factor  $\beta_1$  (TGF- $\beta_1$ ) is a key regulatory factor involved in the proliferation and differentiation of fibroblasts [6]. Recent pharmacological studies targeting TGF- $\beta_1$  have reported progress in the development of myocardial fibrosis treatments [7], but the clinical efficacy of these treatments has yet to be established.

Traditional Chinese medicine (TCM) employs mixtures of multiple herbs to treat patients. These mixtures are referred to as formulas or “Fufang”. It is currently thought that the therapeutic effects that have been demonstrated for many specific TCM therapies are mediated by multiple ingredients. Pharmacologically active ingredients have been demonstrated to be present in several of these formulas, and some of these formulas have been reported to be therapeutically effective against multiple diseases, including tumors, inflammatory conditions and cardiac diseases [8].

Spontaneously hypertensive rat (SHR) is a well-established model for studying the mechanisms of hypertrophy and heart failure associated with genetic hypertension. SHR is often used as a model of human essential hypertension-induced myocardial fibrosis [9]. The SHR develops hypertension at 2 to 6 weeks, followed by progressive myocardial fibrosis, cardiac hypertrophy, and eventual heart failure [10, 11]. Typical symptoms of myocardial fibrosis include left ventricular hypertrophy (LVH) and age-related collagen increase [12]. Several groups reported myocardial collagen concentration and elevated collagen synthesis in SHR when compared with WKY rats of similar age [13, 14]. The myocardial fibrosis and hypertrophy in SHR can be prevented using specific antihypertensive agents [15].

Numerous studies published in the Chinese medical literature have reported the successful treatment of symptoms related to high blood pressure, such as headaches and dizziness, using the herbal formulas Xue-Fu-Zhu-Yu decoction (XFZYD), Tian-Ma-Gou-Teng-Yin (TMGTY) and Wen-Dan decoction (WDD) [16, 17]. Previous studies showed that the three Chinese formulas have significant effects on a variety of hypertension caused cardiovascular diseases. For example, TMGTY can counteract myocardial fibrosis in SHR by reducing LVI and collagen content [18]. Otherwise, the effect of TMGTY on arterial pressure was through an action of TMGTY on sympathetic vasomotor activity [19]. XFZYD improves endothelial function and the state before hypertensive thrombosis in the vessels of the SHRs with hypertension and reduces the formation of myocardial collagen and III [20]. XFZYD could also improve the ischemic necrosis and promoting the angiogenesis [21]. WDD effectively regulates the lipid metabolism, prevent and treat the hyperlipidemia induced diseases in SHR [22]. Therefore, we assume that three Chinese formulas have effect on reversion of hypertensive myocardial fibrosis in SHR. However, the underlying mechanisms of action and therapeutic effects of treatment with these herbal formulas remain unclear.

The present study aimed to investigate whether XFZYD, TMGTY or WDD were capable of reversing myocardial fibrosis in SHR and to elucidate the mechanisms underlying any therapeutic effects found.

## Methods

### Drug preparation

Traditional Chinese herb granules manufactured by Guangdong EFONG Pharmaceutical Co. Ltd. (Guangzhou, China) were purchased from the pharmacy of Southern Hospital. Captopril tablets (12.5 mg) were purchased from Bristol-Myers Squibb Co. Ltd. (Shanghai, China; Lot number: 1209031). The components comprising the TMGTY, WDD and XFZYD formulas are listed in Table 1, and are based on established quality control procedures [8, 19, 23]. After preparation, the herbal mixtures were freeze-dried. Prior to use, each 2 g of dry herbal mixture was resuspended in 1 ml distilled water.

### Animal studies

Forty-five 12-wk-old male SHRs (280 – 320 g) and five age-matched male Wistar-Kyoto (WKY) rats (285–310 g) were purchased from VITAL RIVER Co. Ltd. (Beijing, China; certificate number, SCXK2012-001). SHRs were selected based on total hypertension and established myocardial fibrosis. The WKY rats were used as controls. All rats were maintained in plastic cages with soft bedding under a 12/12 h light–dark cycle. The rats received standard care and had free access to a standard diet and

**Table 1** Composition of Chinese herbal formulas

Components	Source	Amount used (g)	Lot number
Tian-Ma-Gou-Teng-Yin (TMGTY)			
<i>Gastrodia elata</i> Blume	Root	9	407233 T
<i>Uncaria rhynchophylla</i> (Miq.) Miq. ExHavil.	Hook	12	404145 T
<i>Reynoutria multiflora</i> (Thunb.) Moldenke	Aerial part	9	404203 T
<i>Haliotis diversicolor</i> Reeve	Conch	18	311190 T
<i>Eucommia ulmoides</i> Oliv.	Cortex	9	407270 T
<i>Scutellaria baicalensis</i> Georgi	Root	9	409032 T
<i>Gardenia jasminoides</i> J.Ellis	Fruit	9	407018 T
<i>Leonurus japonicus</i> Houtt.	Aerial part	9	409112 T
<i>Viscum coloratum</i> (Kom.) Nakai	Stem	9	408443 T
<i>Achyranthes bidentata</i> Blume	Root	12	409081 T
<i>Poria cocos</i> (Schw.) Wolf	Sclerotium	9	406029 T
Wen-Dan decoction (WDD)			
<i>Pinellia ternata</i> (Thunb.) Makino	Tuber	9	408101 T
<i>Citrus × aurantium</i> L.	Young fruit	12	401084 T
<i>Citrus reticulata</i> Blanco	Mature pericarp	9	409424 T
<i>Pleioblastus amarus</i> (Keng) Keng f.	Stem	9	407209 T
<i>Glycyrrhiz auralensis</i> Fisch.	Rhizome	5	408447 T
<i>Poria cocos</i> (Schw.) Wolf	Sclerotium	5	408407 T
Xue-Fu-Zhu-Yu decoction (XFZYD)			
<i>Angelica sinensis</i> (Oliv.) Diels	Root	9	410141 T
<i>Bupleurum chinense</i> DC.	Root	3	407027 T
<i>Carthamus tinctorius</i> L.	Flower	9	408165 T
<i>Citrus aurantium</i> L.	Fruit	6	403011 T
<i>Cyathula officinalis</i> Kuan	Root	9	409101 T
<i>Glycyrrhiza glabra</i> L.	Root	3	408447 T
<i>Ligusticum striatum</i> DC.	Root	5	410141 T
<i>Paeonia lactiflora</i> Pall.	Root	6	407380 T
<i>Platycodon grandiflorus</i> (Jacq.) A. DC.	Root	5	408059 T
<i>Prunus persica</i> (L.) Batsch.	Seed	12	406423 T
<i>Rehmannia glutinosa</i> (Gaertn.) DC.	Root	9	403409 T

drinking water. The protocol of this study was reviewed and approved by the Animal Review Board of Southern Medical University (Guangzhou, China). The research was conducted under the Animal [Scientific Procedures] Act of 1986 and the institutional guidelines of Southern Medical University for the care and use of animals.

The SHR were randomized into nine groups with five rats in each group. The group 1 rats were treated with distilled water and served as the SHR no-treatment

control group. Groups 2 and 3 were treated with 6 g·kg<sup>-1</sup> and 12 g·kg<sup>-1</sup> TMGTY, respectively. Groups 4 and 5 were treated with 6 g·kg<sup>-1</sup> and 12 g·kg<sup>-1</sup> WDD, respectively. Groups 6 and 7 were treated with 6 g·kg<sup>-1</sup> and 12 g·kg<sup>-1</sup> XFZYD, respectively. Groups 8 and 9 were treated with 30 mg·kg<sup>-1</sup> and 60 mg·kg<sup>-1</sup> captopril, respectively, and were used as the positive treatment control group. Each SHR was given daily oral administration of the appropriate designated drug. The WKY control rats were also treated with distilled water as similar with the group 1 rats for the blank control. All the rats were fed under Specific Pathogen-Free (SPF) conditions, with fresh, sterilized food, vegetables and water that were changed each day. Bedding was replaced once every two days. Environmental noise was less than 60 dB, temperature was maintained between 23 and 26 °C and humidity was maintained between 40 and 70 %.

The total treatment course was 16 weeks. Rat body weight was monitored each wk and systolic blood pressure was measured before and after each experiment. All rats survived the study, and no significant abnormalities were observed. After the final treatment, rats were anesthetized using 350 mg/kg of 10 % chloral hydrate and then euthanized using cervical dislocation. The heart was quickly removed from each euthanized rat, washed with cold normal saline and then dried with filter paper. One-hundred mg of the left ventricle was removed and stored at -70 °C for further analysis. The remainder of the left ventricle was fixed in 10 % formalin for histology.

#### Systolic blood pressure measurements

Rats were housed in a 37 °C chamber for 10 min for indirect systolic blood pressure measurements, then transferred to a standard blood pressure measurement apparatus that included a heating pad, acrylic restrainer, tail cuff and pulse sensor (NarcoBiosystems, Houston, TX, USA). The tail cuff was connected to a cylinder of compressed air via inlet and outlet valves that allowed steady inflation and deflation of the cuff. Tail cuff pressure was continuously recorded using a solid-state pressure sensor (Sensym, Honeywell Sensing & Control, Inc., Morristown, NJ, USA). Pulse and pressure sensor signals were amplified and then digitized with an analogy-digital board (DT16EZ, Data Translation, Inc., Marlboro, MA, USA) connected to a desktop computer. Labtech Notebook Pro (Laboratory Technology Corp., Wilmington, MA, USA) was used to control and display the procedure online. Inflation and deflation scores and the compression interval were recorded for each rat [24].

#### Hydroxyproline content assay

The chloramine T assay was used to quantify hydroxyproline (HYP) in the tissues collected from the rats in

this study [25]. The apex of the left ventricle of each rat was defatted and lysed. Next, the sample was centrifuged at 4000 rpm for 10 min. After centrifugation, the supernatant was mixed with fresh chloramine T for 10 min, followed by mixture with Ehrlich's reagent at 75 °C for 20 min. Samples were then cooled, and the optical density of each sample was read at 560 nm with a microplate reader (iMark, Bio-Rad laboratories, USA). Prior to measuring each sample, the microplate reader was adjusted using a "blank" sample that was prepared using the same procedure used to prepare the experimental samples, but without any cardiac tissue in the reaction mixture. HYP concentration, expressed as micrograms per milligram of dry heart weight, was then calculated as previously described [26].

#### Histological examination

The remaining ventricular tissue not used in the hydroxyproline content assay was immediately fixed in 10 % formalin, embedded in paraffin, sliced into 5 µm sections and then heated for 2 h in a 65 °C incubator. These sections were stained using the Masson trichrome method to examine myocardial interstitial fibrosis [27]. Each section was photographed at 400 x magnification using a light microscope (CX31, Olympus, Tokyo, Japan). All images were analyzed using Image-pro Plus 6.0 software (Media Cybernetics, Bethesda, MD, USA).

The percentage of collagen present in each microscopic field represented the myocardial interstitial collagen content. The accumulation of collagen content in the interstitial spaces of the left ventricle were assessed using polarized light microscopy and analyzed using Image-pro Plus 6.0 software.

#### Immunohistochemical analysis of TGF-β<sub>1</sub> expression

The middle ring of the left ventricle was fixed in 10 % neutral formalin for 24 h, embedded in paraffin and cut into 4 µm sections. Each section was incubated at 4 °C overnight with anti-TGF-β<sub>1</sub> antibody (1:1000, Proteintech Co., Chicago, IL, USA) and at 37 °C for 30 min with Mo/Rb type I polymer (Genecompany, Guangzhou, China). The streptavidin-biotin-peroxidase complex technique (Histostain Plus Kit, cat. No. 85–8943; Zymed, Life Technologies, Grand Island, NY, USA) was used for immunohistochemical visualization of antibody-bound sections. Sections were observed at 400 x magnification, and TGF-β<sub>1</sub> staining intensity was analyzed using Image-pro Plus 6.0 software. Twenty-five random fields per section were analyzed and combined to obtain a final value for each section.

#### TGF-β<sub>1</sub> mRNA expression measurement

TGF-β<sub>1</sub> mRNA expression was determined using real-time reverse transcription polymerase chain reaction (RT-PCR). Total RNA was extracted from tissues using

Trizol (Sigma, St Louis, MO, USA). RNA yields and purity were assessed by spectrophotometric analysis (Bio-Photometer plus, Eppendorf, Germany). Total RNA (1 µg/µl) transcription was performed using an *in vitro* transcription Kit (PrimeScript RT reagent Kit Perfect Real Time, TaKaRa, Japan). RT-PCR reactions were performed with 20 µl reactions that consisted of 10 µl 2X SYBR Premix ExTaq, 0.4 µl PCR Forward primer (10 µM), 0.4 µl PCR reverse primer (10 µM), 2 µl cDNA, 0.4 µl ROX Reference Dye II and 6.8 µl double-distilled water. PCR was conducted with an initial denaturation step of 95 °C for 30 s, followed by 40 cycles of denaturation at 95 °C for 5 s and 60 °C annealing for 34 s. All RT-PCR reactions were performed in triplicate for each sample. The primer sequences were as follows:

TGF-β<sub>1</sub>

Forward: 5' - CATTGCTGTCCCGTGCAGA - 3'

Reverse: 5' - AGGTAACGCCAGGAATTGTTGCTA - 3'

β-actin

Forward: 5' - TGACGTTGACATCCGTAAGACC - 3'

Reverse: 5' - GTGCTAGGAGCCAGGGCAGTAA - 3'

RT-PCR and data analysis were carried out using ABI 7500 Software 2.0.3 (Life Technologies). Values obtained for TGF-β<sub>1</sub> were normalized against values obtained for β-actin, and the results were expressed as relative integrated intensity.

#### Western blot analysis of TGF-β<sub>1</sub>

Heart tissue was homogenized in ice-cold loading buffer (pH 6.8). Total protein was extracted using RIPA Lysis Buffer (Fu De Biological Technology, Hangzhou, China). The protein was separated using a 12 % SDS-polyacrylamide gel in electrophoresis sample buffer and then transferred to PVDF membranes. After blocking membranes for 1.5 h with 5 % bovine serum albumin (BSA) in tris-buffered saline containing 0.1 % Tween-20 at pH 7.6 (TBST), the membranes were probed overnight at 4 °C with antibodies against TGF-β<sub>1</sub> (1:1500, product number: ab92486, Epitomics, Burlingame, California, USA and Abcam, Cambridge, UK). After the overnight primary antibody incubation, the membranes were washed with TBST, once for 15 min and then an additional three times for 5 min each. After washing, the membranes were incubated with goat anti-rabbit horseradish peroxidase-conjugated secondary antibody (1:6000, product number: #7074, Cell Signaling Technology, Danvers, MA, USA) for 1 h at room temperature and then washed three times with TBST for a total of 30 min. Antibody-antigen complexes were visualized using enhanced chemiluminescence (Millipore, USA). Images were scanned and the results were quantified using Image-pro Plus 6.0 software.

### Statistical analysis

All data were presented as means  $\pm$  standard deviation (SD). Multiple comparisons were performed using one-way ANOVA ( $p < 0.05$ ) followed by Dunnett's post-hoc  $t$ -test. All statistical analyses were performed using SPSS 13.0 software (SPSS Inc. Chicago, IL, USA).

### Results

#### Effects of TCM on systolic blood pressure and body weight

Data obtained during this study were consistent with data reported by previous studies, and indicated that the systolic blood pressure of control SHRs was much higher than that of WKY rats (Table 2,  $p = 0.005$ ). Comparisons among the SHRs treated with WDD, XFZYD, TMGTY and captopril revealed that captopril treatment alone significantly reduced systolic blood pressure ( $p = 0.032$ ). None of the other treatments demonstrated any anti-hypertensive effect ( $p = 0.085$ , WDD;  $p = 0.075$ , XFZYD;  $p = 0.103$ , TMGTY).

#### Effect of TCM on myocardial HYP content

Myocardial HYP content levels are illustrated in Fig. 1. TMGTY, WDD, XFZYD and captopril treatment all significantly reduced the left ventricular HYP content of SHRs. The strongest effect was seen after captopril ( $p < 0.001$ ,  $F = 94.431$ ,  $df = 17$ , low-dose group;  $p = 0.003$ ,  $F = 110.054$ ,  $df = 17$ , high-dose group) and XFZYD ( $p < 0.001$ , low- and high-dose groups) treatment. High dose treatment groups exhibited a stronger HYP reduction than the low dose treatment groups.

#### Effect of TCM on myocardial collagen

Red or deep red normal muscle fibers and blue myocardial interstitial collagen fibers were observed during microscopic examination of Masson trichrome stained tissues (Fig. 2). Generally, less collagen accumulation was seen in the myocardia of WKY tissues when compared with tissues from the SHR control group ( $p = 0.041$ ;  $F = 74.927$ ,

$df = 17$ ; Fig. 2). After treatment, collagen levels were significantly reduced in all treatment groups. Notably, less collagen was deposited in the SHR groups treated with the TCM formulas when compared with the collagen levels of the control SHR group, and both XFZYD (12 g·kg<sup>-1</sup>,  $p = 0.018$ ) and captopril (60 mg·kg<sup>-1</sup>,  $p = 0.007$ ) significantly reduced the post-treatment myocardial collagen levels. The observed reduction in myocardial collagen was not statistically significant after treatment with TMGTY (12 g·kg<sup>-1</sup>,  $p = 0.064$ ) or WDD (12 g·kg<sup>-1</sup>,  $p = 0.092$ ).

#### Effect of TCM on myocardial TGF- $\beta_1$

TGF- $\beta_1$  expression in the myocardial interstitium of SHR controls was significantly increased when compared with the myocardial interstitium of WKY control rats ( $p = 0.039$ ;  $F = 73.108$ ,  $df = 17$ ; Fig. 3). Immunohistochemistry revealed that the captopril (60 mg·kg<sup>-1</sup>,  $p = 0.021$ ) and XFZYD (12 g·kg<sup>-1</sup>,  $p = 0.034$ ) treated groups exhibited significantly reduced brown granule deposits, suggesting that TGF- $\beta_1$  expression was reduced in these groups when compared with the control SHR group (Table 3). The concentrations of brown granule deposits were not significantly different between the TMGTY (12 g·kg<sup>-1</sup>,  $p = 0.071$ ) and WDD (12 g·kg<sup>-1</sup>,  $p = 0.078$ ) treatment groups.

#### TGF- $\beta_1$ mRNA expression in SHR and WKY

TGF- $\beta_1$  mRNA expression was increased in the left ventricles of control SHRs when compared with WKY control rats ( $p = 0.007$ ;  $F = 152.538$ ,  $df = 17$ , low-dose group;  $F = 137.812$ ,  $df = 17$ , high-dose group; Fig. 4). Treatment with captopril (30 mg·kg<sup>-1</sup>,  $p = 0.025$ ; 60 mg·kg<sup>-1</sup>,  $p = 0.009$ ) and XFZYD (12 g·kg<sup>-1</sup>,  $p = 0.031$ ) significantly reduced TGF- $\beta_1$  mRNA expression in a dose-dependent manner. In contrast, neither TMGTY (6 g·kg<sup>-1</sup>,  $p = 0.095$ ; 12 g·kg<sup>-1</sup>,  $p = 0.076$ ) nor WDD (6 g·kg<sup>-1</sup>,  $p = 0.101$ ; 12 g·kg<sup>-1</sup>,  $p = 0.078$ ) treatment had any effect on TGF- $\beta_1$  mRNA expression.

**Table 2** Effects of TCM on systolic blood pressure and body weight

	WKY	SHRs								
		Control	TMGTY		WDD		XFZYD		CAPTOPRIL	
			6 g·kg <sup>-1</sup>	12 g·kg <sup>-1</sup>	6 g·kg <sup>-1</sup>	12 g·kg <sup>-1</sup>	6 g·kg <sup>-1</sup>	12 g·kg <sup>-1</sup>	30 mg·kg <sup>-1</sup>	60 mg·kg <sup>-1</sup>
Systolic blood pressure (mmHg)										
Before	123 $\pm$ 13	177 $\pm$ 8**	173 $\pm$ 13	176 $\pm$ 9	175 $\pm$ 11	179 $\pm$ 7	172 $\pm$ 14	170 $\pm$ 16	177 $\pm$ 13	178 $\pm$ 11
After	128 $\pm$ 11	188 $\pm$ 6**	179 $\pm$ 8	178 $\pm$ 6	177 $\pm$ 7	180 $\pm$ 9	170 $\pm$ 12	168 $\pm$ 5	161 $\pm$ 10***	153 $\pm$ 9***
Body weight (g)										
Before	299 $\pm$ 7	310 $\pm$ 5	305 $\pm$ 9	303 $\pm$ 6	302 $\pm$ 7	306 $\pm$ 7	294 $\pm$ 11	298 $\pm$ 8	305 $\pm$ 7	302 $\pm$ 10
After	361 $\pm$ 12	363 $\pm$ 4	345 $\pm$ 10	351 $\pm$ 11	342 $\pm$ 13	336 $\pm$ 5	332 $\pm$ 10	330 $\pm$ 9	330 $\pm$ 8	329 $\pm$ 14

\*\* $p < 0.01$  compared to the WKY rats, \*\*\* $p < 0.05$  compared to the SHR control  
\* $p < 0.05$  compared to the corresponding data before the experiment

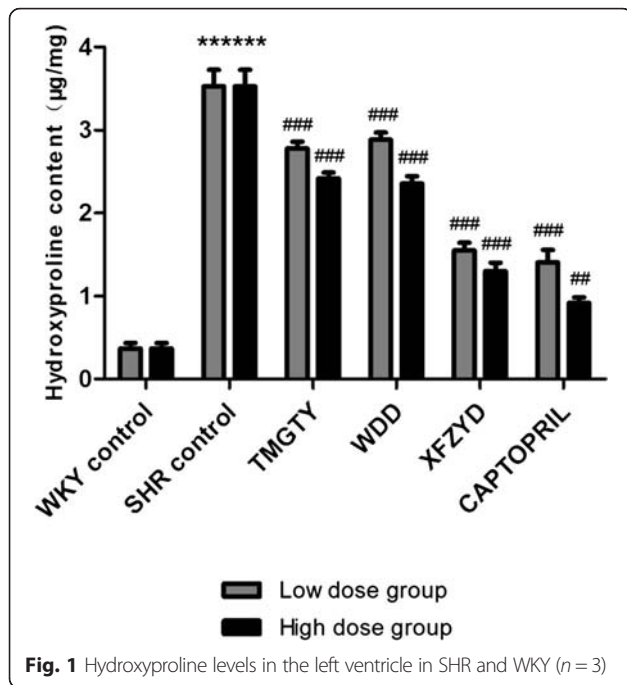


Fig. 1 Hydroxyproline levels in the left ventricle in SHR and WKY (n = 3)

**TGF-β<sub>1</sub> protein expression in SHR and WKY**

TGF-β<sub>1</sub> protein expression differed significantly between the control SHR group and the WKY control group ( $p < 0.001$ ;  $F = 1408.471$ ,  $df = 17$ ; Fig. 5). Furthermore, TGF-β<sub>1</sub> protein expression in SHR was significantly decreased in the captopril (60 mg·kg<sup>-1</sup>) and XFZYD (12 g·kg<sup>-1</sup>) treatment groups when compared with the control SHR group ( $p < 0.001$ ). Treatment with WDD (12 g·kg<sup>-1</sup>) also markedly reduced TGF-β<sub>1</sub> protein expression when compared with the control SHR group ( $p = 0.036$ ). In contrast, TMGTY (12 g·kg<sup>-1</sup>) treatment was not associated with a

statistically significant decrease in TGF-β<sub>1</sub> protein expression ( $p = 0.064$ ).

**Discussion**

Systemic hypertension is a highly prevalent chronic disease and a significant determinant of cardiovascular morbidity and mortality [28, 29]. It is a primary cause of myocardial fibrosis, which in turn plays a key role in the pathophysiology of hypertension-induced cardiac damage [30]. Myocardial fibrosis is the excessive deposition of collagen fibers in myocardial tissue [31], and has been closely associated with hypertension, myocardial infarction, atherosclerosis and diabetes. Thus, the inhibition of early hypertension may delay ventricular remodeling and heart failure [32].

Captopril is an angiotensin-converting enzyme inhibitor that is used as an anti-hypertensive agent. It is also ameliorates myocardial fibrosis [33], and is used to treat certain types of congestive heart failure [34]. In this study, we compared the efficacy of captopril with three different Chinese herbal formulas derived from TCM for the treatment of myocardial fibrosis in SHRs.

The baseline blood pressure measured in this study was much higher in SHRs when compared with the baseline blood pressure in WKY rats. WDD, XFZYD and TMGTY treatment had no effect on the systolic blood pressure, whereas captopril treatment significantly reduced the systolic blood pressure measured in SHRs. XFZYD treatment at 12 g·kg<sup>-1</sup> each day for 16 weeks effectively inhibited myocardial fibrosis and decreased HYP in SHR myocardial tissue. Our results suggest that the XFZYD induced reduction in fibrosis and HYP content was independent of blood pressure, providing a theoretical basis for the clinical application of XFZYD.

Cardiac hypertrophy and interstitial fibrosis are common outcomes after cardiac injury and overload [35, 36].

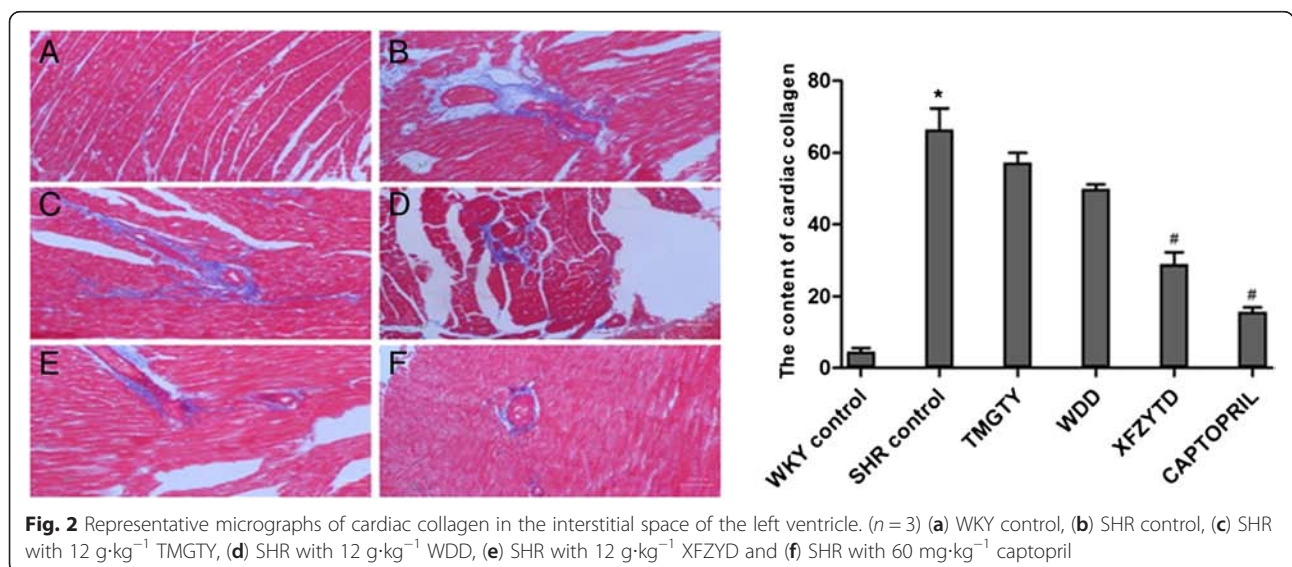
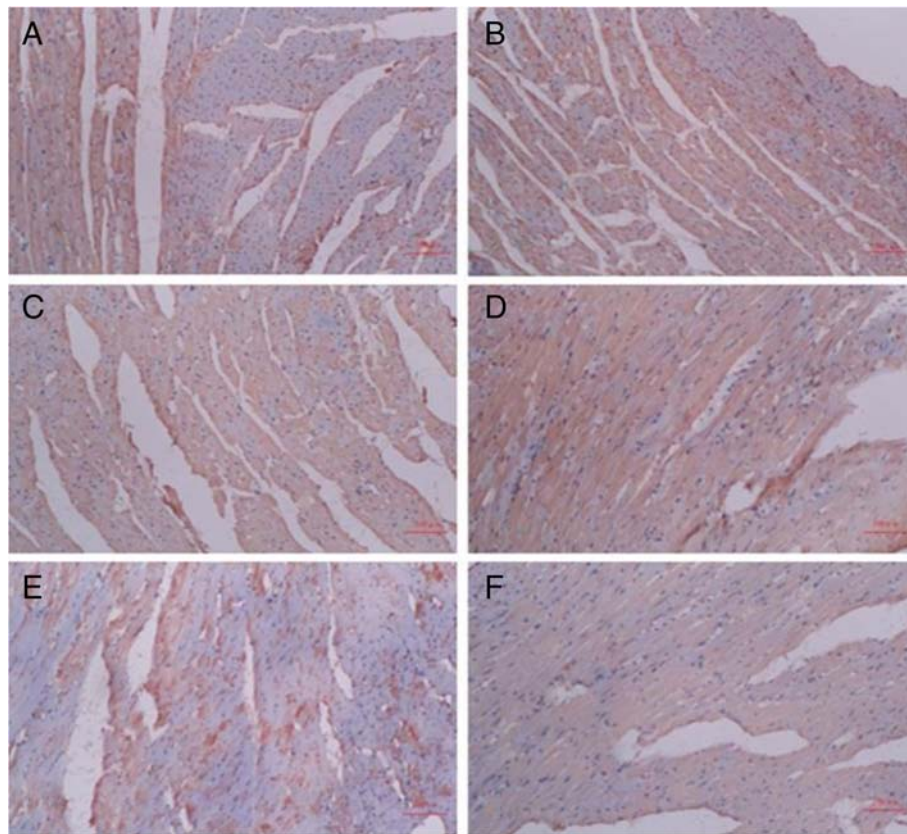


Fig. 2 Representative micrographs of cardiac collagen in the interstitial space of the left ventricle. (n = 3) (a) WKY control, (b) SHR control, (c) SHR with 12 g·kg<sup>-1</sup> TMGTY, (d) SHR with 12 g·kg<sup>-1</sup> WDD, (e) SHR with 12 g·kg<sup>-1</sup> XFZYD and (f) SHR with 60 mg·kg<sup>-1</sup> captopril



**Fig. 3** Representative micrographs of TGF-β<sub>1</sub> protein expression in myocardial tissue. (n = 3) (a) WKY control, (b) SHR control, (c) SHR with 12 g·kg<sup>-1</sup> TMGTY, (d) SHR with 12 g·kg<sup>-1</sup> WDD, (e) SHR with 12 g·kg<sup>-1</sup> XFZYD and (f) SHR with 60 mg·kg<sup>-1</sup> captopril

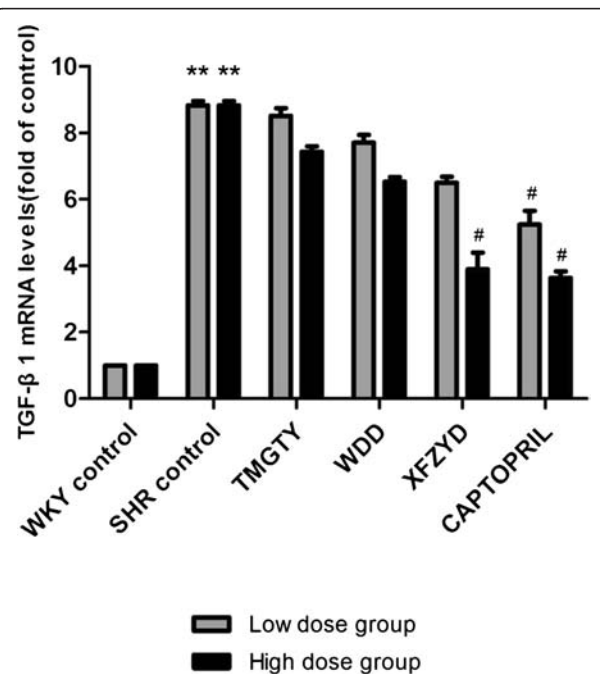
TGF-β overexpression is a clear factor underlying tissue fibrosis development in numerous human diseases. Furthermore, TGF-β plays a crucial role in pathogenic processes associated with cardiac remodeling and fibrosis [37], and the over expression of cardiac TGF-β<sub>1</sub> is associated with both fibrosis and hypertrophy [38].

Using immunohistochemical, RT-PCR and Western blot analysis, we confirmed that the expression of TGF-β<sub>1</sub> mRNA and protein was reduced in SHRs after 16 weeks of daily treatment with 12 g·kg<sup>-1</sup> XFZYD. We conclude that XFZYD inhibited fibrosis by disrupting the TGF-β signaling pathway. Other TCM treatments had no significant effects.

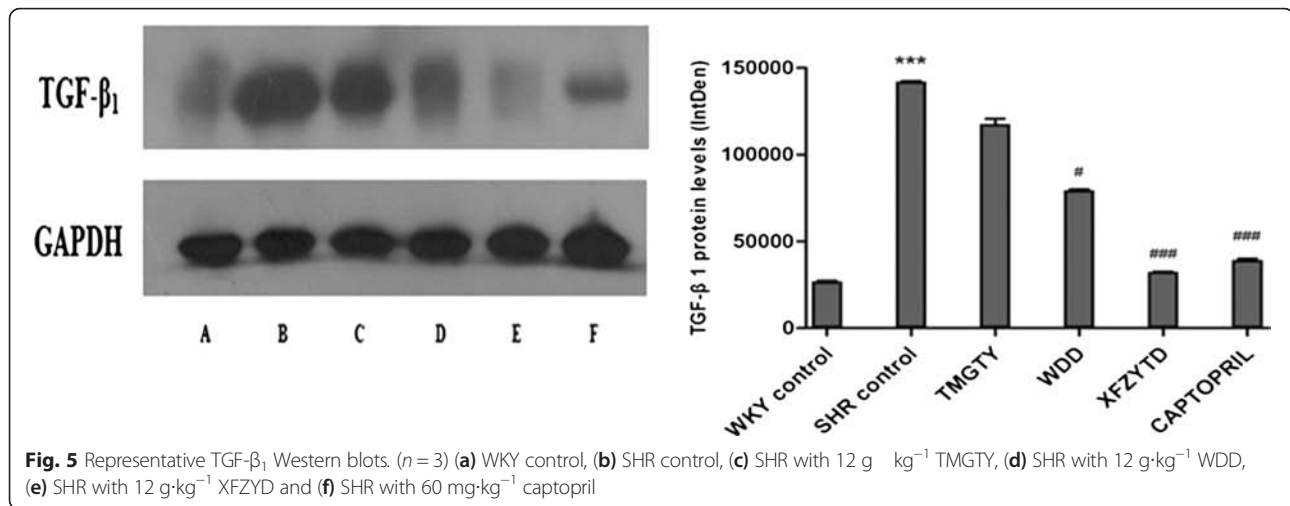
**Table 3** Effects of TCM on myocardial TGF-β<sub>1</sub>

Sample	IOD	Area(μm <sup>2</sup> )	Density
WKY control	1839 ± 75	2290 ± 122	0.81 ± 0.07
SHR control	1225 ± 39	1018 ± 20	1.20 ± 0.01*
TMGTY	1306 ± 74	1179 ± 58	1.12 ± 0.12
WDD	1740 ± 46	1580 ± 85	1.11 ± 0.08
XFZYTD	921 ± 43	1009 ± 43	0.92 ± 0.09**
CAPTOPRIL	591 ± 60	708 ± 11	0.83 ± 0.07**

\*p < 0.05 compared to the WKY control, \*\*p < 0.05 compared to the SHR control



**Fig. 4** TGF-β<sub>1</sub> mRNA expression in SHR and WKY. (n = 3)



XFZYD is a classic formula in TCM clinical for treatment of heart disease, our study found that XFZYD has the effect of reverse hypertensive myocardial fibrosis and the mechanism may be associated with TGF- $\beta_1$  signaling pathways. So we speculate that there are some active components in the formula of XFZYD to ameliorate hypertensive myocardial fibrosis through TGF- $\beta_1$  signaling pathways. Studies show that XFZYD not only can inhibit myocardial fibroblasts proliferation, but also to disturb the action of collagen secretion by myocardial fibroblasts [39]. Ferulic acid sodium is the main active ingredient in *Angelica sinensis* (Oliv.) Diels, the structure contains phenolic hydroxyl, which has the function of antioxidant and antiatherosclerosis. Ferulic acid sodium can suppress the cardiac fibroblasts proliferation induced by AngII, which exhibit a dose-dependent effect, the mechanism may be associated with lower TGF- $\beta_1$  protein expression [40]. Ligustrazine is the main component of *Ligusticum striatum* DC., which can block and delay the development of myocardial fibrosis in chronic pressure overload rats and also inhibit the myocardial fibroblasts induced by AngII [41]. Carthamin yellow is extracted from *Carthamus tinctorius* L., which can inhibit AngII and ACE and also play a good role in cardiovascular protection [42]. Amygdalin in *Prunus persica* (L.) Batsch has the effect of ameliorate hepatic fibrosis [43]. Paeoniflorin in *Paeonia lactiflora* Pall. has protective effect on myocardium in rats [44]. The existing research results are consistent with our conclusion, which can support each other. We can infer that the effective components of XFZYD formula to ameliorate myocardial fibrosis through TGF- $\beta_1$  signaling pathways may have close relationship with ferulic acid sodium, ligustrazine, carthamin yellow, amygdalin and paeoniflorin which are extracted respectively from *Angelica sinensis* (Oliv.) Diels, *Ligusticum striatum* DC., *Carthamus tinctorius* L., *Prunus persica* (L.) Batsch and *Paeonia lactiflora* Pall.

We plans to research the demolition party of XFZYD in next step, and focus on the relationship between each active ingredient and TGF- $\beta_1$  signaling pathway, in order to screen out the exact active ingredients to reverse hypertensive myocardial fibrosis in XFZYD.

## Conclusion

Among the three TCM formulas tested in this study, we found that only XFZYD was capable of reversing myocardial fibrosis. We also found that XFZYD treatment decreased hypertension-induced cardiac fibrosis independent of systolic blood pressure. Future clinical studies are needed to evaluate the therapeutic benefit of XFZYD in patients with hypertension. This study demonstrates that XFZYD decreases cardiac fibrosis via TGF- $\beta_1$  signaling pathway.

## Additional files

- Additional file 1:** The protocol of animal experimental. (DOCX 796 kb)
- Additional file 2:** The approval of the Southern Medical University Animal Cave and Use Committee. (DOCX 1607 kb)
- Additional file 3:** The constitution of the Southern Medical University Animal Cave and Use Committee. (DOCX 3226 kb)
- Additional file 4:** The staff of the Southern Medical University Animal Cave and Use Committee. (DOCX 658 kb)
- Additional file 5:** The HPLC results for the quality control of the herbs. (PDF 27 kb)

## Abbreviations

CVF: Collagen volume fraction; SBP: Systolic blood pressure; SHR: Spontaneously hypertensive rat; TCM: Traditional Chinese Medicine; TMGTY: Tian-Ma-Gou-Teng-Yin; WDD: Wen-Dan decoction; WKY: Wistar-Kyoto rats; XFZYD: Xue-Fu-Zhu-Yu decoction.

## Competing interests

The authors declare that they have no competing interests.



**Authors' contributions**

LL and GZ designed the study. GZ and GY performed the experiments. XZ and WW analyzed data. LL and GY wrote the manuscript. JH, JR and YY revised the manuscript. All authors read and approved the final manuscript. GZ and GY contributed equally to this work and should be considered co-first authors.

**Acknowledgements**

This study was supported by The National Natural Science Foundation, grant numbers 81072937 and 81373811 from the Science Fund Committee of China.

**Author details**

<sup>1</sup>School of Traditional Chinese Medicine, Southern Medical University, 1838 Guangzhou Avenue North, Guangzhou, P. R. China. <sup>2</sup>School of Pharmaceutical Sciences, Southern Medical University, 1838 Guangzhou Avenue North, Guangzhou, P. R. China.

Received: 14 April 2015 Accepted: 29 January 2016

**References**

- Ozawa K, Funabashi N, Kataoka A, Tanabe N, Yanagawa N, Tatsumi K, et al. Myocardial fibrosis in the right ventricle detected on ECG gated 320 slice CT showed a short term poor prognosis in subjects with pulmonary hypertension. *Int J Cardiol.* 2013;168(1):584–6.
- Medvedev NV, Gorshukova NK. Pathogenetic significance of interstitial fibrosis in development myocardial dysfunction and chronic heart failure in elderly patients with arterial hypertension. *Adv Gerontol.* 2013;26(1):130–6.
- Sowers JR. Hypertension myocardial fibrosis. *J Clin Hypertens.* 2007; 9(7):558–9.
- Xu X, Tan X, Tampe B, Nyamsuren G, Liu X, Maier LS, et al. Epigenetic balance of aberrant Ras1 promoter methylation and hydroxymethylation regulates cardiac fibrosis. *Cardiovasc Res.* 2015;105(3):279–91.
- Khan R, Sheppard R. Fibrosis in heart disease: understanding the role of transforming growth factor-beta in cardiomyopathy, valvular disease and arrhythmia. *Immunology.* 2006;118(1):10–24.
- Leask A. TGFbeta, cardiac fibroblasts, and the fibrotic response. *Cardiovasc Res.* 2007;74(2):207–12.
- Yoshimatsu Y, Watabe T. Roles of TGF-beta signals in endothelial-mesenchymal transition during cardiac fibrosis. *Int J Inflamm.* 2011;2011: 724080.
- Lee JJ, Hsu WH, Yen TL, Chang NC, Luo YJ, Hsiao G, et al. Traditional Chinese medicine, Xue-Fu-Zhu-Yu decoction, potentiates tissue plasminogen activator against thromboembolic stroke in rats. *J Ethnopharmacol.* 2011;134(3):824–30.
- Ziegelhoffer-Mihalovicova B, Arnold N, Marx G, Tannapfel A, Zimmer HG, Rassler B. Effects of salt loading and various therapies on cardiac hypertrophy and fibrosis in young spontaneously hypertensive rats. *Life Sci.* 2006;79(9):838–46.
- Bing OH, Brooks WW, Robinson KG, Slawsky MT, Hayes JA, Litwin SE, et al. The spontaneously hypertensive rat as a model of the transition from compensated left ventricular hypertrophy to failure. *J Mol Cell Cardiol.* 1995; 27(1):383–96.
- Conrad CH, Brooks WW, Hayes JA, Sen S, Robinson KG, Bing OH. Myocardial fibrosis and stiffness with hypertrophy and heart failure in the spontaneously hypertensive rat. *Circulation.* 1995;91(1):161–70.
- Engelmann GL, Vitullo JC, Gerrity RG. Morphometric analysis of cardiac hypertrophy during development, maturation, and senescence in spontaneously hypertensive rats. *Circ Res.* 1987;60(4):487–94.
- Cutilletta AF, Erinoff L, Heller A, Low J, Oparil S. Development of left ventricular hypertrophy in young spontaneously hypertensive rats after peripheral sympathectomy. *Circ Res.* 1977;40(4):428–34.
- Sen S, Bumpus FM. Collagen synthesis in development and reversal of cardiac hypertrophy in spontaneously hypertensive rats. *Am J Cardiol.* 1979; 44(5):954–8.
- Sen S, Tarazi RC, Khairallah PA, Bumpus FM. Cardiac hypertrophy in spontaneously hypertensive rats. *Circ Res.* 1974;35(5):775–81.
- Xue M, Chen KJ, Ma XJ, Liu JG, Jiang YR, Miao Y, et al. Effects of Xuefu Zhuyu Oral Liquid on hemorheology in patients with blood-stasis syndrome due to coronary disease and their relationship with human platelet antigen-3 polymorphism. *Zhong Xi Yi Jie He Xue Bao.* 2008;6(11):1129–35.
- Li Y, Chen K, Shi Z. Effect of xuefu zhuyu pill on blood stasis syndrome and risk factor of atherosclerosis. *Zhongguo Zhong Xi Yi Jie He Za Zhi.* 1998; 18(2):71–3.
- Shiyun HU, Shaoxiang X, Licheng Z. Effect of tianma gouteng decoction on myocardial fibrosis in renovascular hypertensive rats. *Traditional Chinese drug research & clinical pharmacology.* 2006;17(2):97–9.
- Zhang TX, Wang YF, Ciriello J. The herbal medicine tian ma gou teng yen alters the development of high blood pressure in the spontaneously hypertensive rat. *Am J Chin Med.* 1989;17(3–4):211–9.
- Zhong-qiang Ji, Wen-hui WU, Wen-yan Ji. Mechanism study of the impacts on myocardial fibrosis treated with modified xuefu zhuyu decoction in the rats with hypertension. *World journal of integrated of traditional and western medicine.* 2011;06(5):385–8.
- Gao D, Jiao YH, Wu YM. Experimental study of Xuefu Zhuyu Decoction induced participation of endothelial progenitor cells in the angiogenesis of the ischemic region. *Zhongguo Zhong Xi Yi Jie He Za Zhi.* 2012;32(2):224–8.
- Guohua Z. Effect of Wendan decoction on lipid metabolism in hyperlipidemic adult rats. *Hebei journal of traditional Chinese medicine.* 2007;7(5):28–9.
- Wang L, Song Y, Li F, Liu Y, Ma J, Mao M, et al. Effects of Wen Dan Tang on insomnia-related anxiety and levels of the brain-gut peptide Ghrelin. *Neural regeneration research.* 2014;9(2):205–12.
- Fritz M, Rinaldi G. Blood pressure measurement with the tail-cuff method in Wistar and spontaneously hypertensive rats: influence of adrenergic- and nitric oxide-mediated vasomotion. *J Pharmacol Toxicol Methods.* 2008;58(3):215–21.
- Jia H, Chen XL, Chen C, Hu YY, Yun XJ. Baicalin prevents the up-regulation of connective tissue growth factor in fibrotic lungs of rats. *Sheng Li Xue Bao.* 2010;62(6):535–40.
- Zhai Y, Gao X, Wu Q, Peng L, Lin J, Zuo Z. Fluvastatin decreases cardiac fibrosis possibly through regulation of TGF-beta(1)/Smad 7 expression in the spontaneously hypertensive rats. *Eur J Pharmacol.* 2008;587(1–3):196–203.
- Akashiba A, Ono H, Ono Y, Ishimitsu T, Matsuoka H. Valsartan improves L-NAME-exacerbated cardiac fibrosis with TGF-ss inhibition and apoptosis induction in spontaneously hypertensive rats. *J Cardiol.* 2008;52(3):239–46.
- Haider AW, Larson MG, Benjamin EJ, Levy D. Increased left ventricular mass and hypertrophy are associated with increased risk for sudden death. *J Am Coll Cardiol.* 1998;32(5):1454–9.
- Assayag P, Carre F, Chevalier B, Delcayre C, Mansier P, Swynghedauw B. Compensated cardiac hypertrophy: arrhythmogenicity and the new myocardial phenotype. I. Fibrosis. *Cardiovasc Res.* 1997;34(3):439–44.
- Fortuno MA, Ravassa S, Fortuno A, Zalba G, Diez J. Cardiomyocyte apoptotic cell death in arterial hypertension: mechanisms and potential management. *Hypertension.* 2001;38(6):1406–12.
- Diez J. Mechanisms of cardiac fibrosis in hypertension. *J Clin Hypertens.* 2007;9(7):546–50.
- Caglayan E, Stauber B, Collins AR, Lyon CJ, Yin F, Liu J, et al. Differential roles of cardiomyocyte and macrophage peroxisome proliferator-activated receptor gamma in cardiac fibrosis. *Diabetes.* 2008;57(9):2470–9.
- Rossi MA, Peres LC. Effect of captopril on the prevention and regression of myocardial cell hypertrophy and interstitial fibrosis in pressure overload cardiac hypertrophy. *Am Heart J.* 1992;124(3):700–9.
- Rodríguez-Vita J, Sanchez-Lopez E, Esteban V, Ruperez M, Egidio J, Ruiz-Ortega M. Angiotensin II activates the Smad pathway in vascular smooth muscle cells by a transforming growth factor-beta-independent mechanism. *Circulation.* 2005;111(19):2509–17.
- Simko F. Physiologic and pathologic myocardial hypertrophy—physiologic and pathologic regression of hypertrophy? *Med Hypotheses.* 2002;58(1):11–4.
- Cohn JN, Ferrari R, Sharpe N. Cardiac remodeling—concepts and clinical implications: a consensus paper from an international forum on cardiac remodeling. *Behalf of an International Forum on Cardiac Remodeling.* *J Am Coll Cardiol.* 2000;35(3):569–82.
- Massague J. The transforming growth factor-beta family. *Annu Rev Cell Biol.* 1990;6:597–641.
- Dobaczewski M, Chen W, Frangogiannis NG. Transforming growth factor (TGF)-beta signaling in cardiac remodeling. *J Mol Cell Cardiol.* 2011; 51(4):600–6.
- Zhishan D, Chengxian G, Ruirui J, Xingde W. Effects of XueFuZhuYu decoction on collagen synthesis and proliferation of cardiac fibroblasts. *Journal of Chinese Medicinal Materials.* 2002;07:481–3.

40. Miya Y, Jingping O, Yanfang Z: Effects of Sodiumferulate on the Proliferation of Cardiac Fibroblasts. *Medical Journal of Wuhan University* 2006(02):148-151+278.
41. Hailing R, Shisen J, Dujiang X, Chunhui W, Tao H: Effect of Ligustrazine on myocardial fibrosis in rats with pressure overload. *Mod Rehab.* 2003;(12): 1748-1749+1875.
42. Fa L, Yuan W, Xinzhong Y, Fanggui L, Jian H, Ruifen C. The antihypertensive effect of carthamin yellow and the impact on renin angiotensin in hypertensive rats. *Acta Pharmaceutica Sinica.* 1992;10:785-7.
43. Guangsheng Y, Mingui T, Wangchun R, Jiahe H, Zhabang Z, Yongzhen H, et al. Peach kernel research for the treatment of schistosomiasis cirrhosis. *J Tradit Chin Med.* 1986;06:24-5.
44. Chunfu W. Research on the pharmacological of peony and its chemical constituents. *Traditional Chinese Medicine Bulletin.* 1985;06:45-7.

Submit your next manuscript to BioMed Central and we will help you at every step:

- We accept pre-submission inquiries
- Our selector tool helps you to find the most relevant journal
- We provide round the clock customer support
- Convenient online submission
- Thorough peer review
- Inclusion in PubMed and all major indexing services
- Maximum visibility for your research

Submit your manuscript at  
[www.biomedcentral.com/submit](http://www.biomedcentral.com/submit)

